



Equine Wound Care

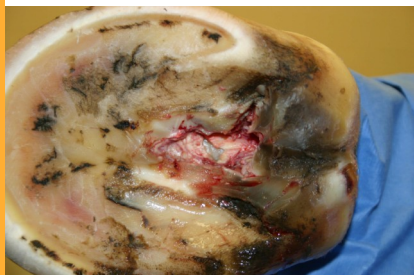Punctures to the Hoof

SPECIAL POINTS OF INTEREST:

- **Don't Panic!**
Remain calm and keep your horse calm.
- **Be Prepared!**
Have access to your veterinarians contact information.
- **Place your horse in a quiet, well-lit area until your veterinarian is available for consultation.**
- **Have a well-stocked first aid kit ready for emergencies.**
- **If there is possibility of the object to go deeper, remove it. If not, leave the penetrating object in place until your veterinarian is available.**

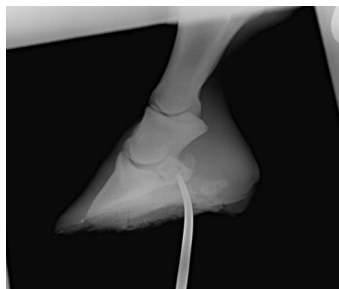
Emergency First Aid

Puncture wounds into the hoof are rarely minor. Early, aggressive therapy is imperative to have a positive outcome. They usually seem inconsequential, a small nail or wood splinter. For the average horse owner, the first thought will be to remove the object, clean the foot, and watch it for any problems. This is the completely wrong thing to do. Although puncture wounds of the sole can appear small, they are often deep and can have disastrous consequences. When dealing with puncture wounds to the foot, time is of the essence. There are many important structures within the hoof capsule and they only protected by millimeters of hoof capsule and sole. Based on location and depth of the puncture wound, various critical structures such as, coffin bone, navicular bone, navicular bursa, deep digital flexor tendon sheath, and the coffin joint can be



Hoof debridement at surgery. Notice the large area of the wound. It is in the shape of the penetrating object, a T-post. In the center of the wound you can see the white of the navicular bone.

penetrated. Even if vital structures are missed, the damage done to the soft tissues will become a good environment for bacterial growth and therefore, infection.



Radio-opaque instrument locating the penetrating objects path. Notice its path went through the deep digital flexor tendon, navicular bursa, and contacted the navicular bone.

Anytime you suspect a puncture wound you should call your veterinarian immediately. If you find your horse with the penetrating object still in the hoof, you should leave it until your veterinarian arrives to visually and radiographically inspect it. If you think the object could potentially go deeper and do more damage, you might consider removing it. A picture of the location or a mark on the sole would be beneficial for the veterinarian to identify the entry point. If your veterinarian cannot arrive immedi-

ately, you can place a well-padded foot bandage on the foot to keep direct pressure off of the sole of the foot.

Puncture wounds of the frog and sole are readily missed. The entry site tends to cover up as the object comes out. If the penetrating object remains in place, the horse will usually be lame immediately. Some horses may remain comfortable if the object comes out until infection sets in. With the object left in place, radiographs can allow you to determine the extent of the penetrating object. If there is no object in place, an instrument, probe, or contrast agent can be passed in the tract to determine the extent of the tract.

If you suspect your horse to have a puncture wound, we encourage you to call us immediately at Conley and Koontz Equine Hospital. At a minimum our veterinarians can debride the damaged tissues and treat the horse aggressively to have a positive outcome.



A piece of mulch, which was completely hidden is found while debriding the frog.